

■ FOOT AND ANKLE

The treatment of a rupture of the Achilles tendon using a dedicated management programme

A. M. Hutchison,
C. Topliss,
D. Beard,
R. M. Evans,
P. Williams

*From Morriston
Hospital, ABMU
University Health
Board, Swansea,
United Kingdom*

■ A. M. Hutchison, BSc Hons, MSc, PhD, Advanced Practitioner Physiotherapist and Honorary Senior Lecturer (Swansea University)
■ C. Topliss, MB BS, FRCS(Tr&Orth), MD, Consultant in Trauma and Orthopaedic Surgery
■ P. Williams, BSc Hons, MB BCh, FRCS (Tr&Orth), Consultant Trauma & Orthopaedic Surgeon Morriston Hospital, ABMU Health Board, Orthopaedic Department, Swansea, SA6 6NL, UK.

■ D. Beard, MA, MSc, DPhil, Professor of Musculoskeletal Sciences University of Oxford & Morriston Hospital, Institute of Musculoskeletal Sciences, Swansea, UK.

■ R. M. Evans, MB BCh FRCR, Consultant Radiologist, Assoc. Professor of Imaging Morriston Hospital / Swansea University College of Medicine, Radiology Dept, Morriston Swansea, SA6 6NL, UK.

Correspondence should be sent to Dr A. M. Hutchison; e-mail: Anne-Marie.Hutchison@wales.nhs.uk

©2015 The British Editorial Society of Bone & Joint Surgery
doi:10.1302/0301-620X.97B4.35314 \$2.00

Bone Joint J
2015;97-B:510–15.
Received 23 October 2014;
Accepted after revision 12
December 2014

The Swansea Morriston Achilles Rupture Treatment (SMART) programme was introduced in 2008. This paper summarises the outcome of this programme. Patients with a rupture of the Achilles tendon treated in our unit follow a comprehensive management protocol that includes a dedicated Achilles clinic, ultrasound examination, the use of functional orthoses, early weight-bearing, an accelerated exercise regime and guidelines for return to work and sport. The choice of conservative or surgical treatment was based on ultrasound findings.

The rate of re-rupture, the outcome using the Achilles Tendon Total Rupture Score (ATRS) and the Achilles Tendon Repair Score, (AS), and the complications were recorded. An elementary cost analysis was also performed.

Between 2008 and 2014 a total of 273 patients presented with an acute rupture 211 of whom were managed conservatively and 62 had surgical repair. There were three re-ruptures (1.1%). There were 215 men and 58 women with a mean age of 46.5 years (20 to 86). Functional outcome was satisfactory. Mean ATRS and AS at four months was 53.0 (SD 14), 64.9 (SD 15) (n = 135), six months 67.8 (SD 16), 73.8 (SD 15) (n = 103) and nine months (72.4; SD 14) 72.3 (SD 13) (n = 43). The programme realised estimated cost savings exceeding £91 000 per annum.

The SMART programme resulted in a low rate of re-rupture, a satisfactory outcome, a reduced rate of surgical intervention and a reduction in healthcare costs.

Cite this article: *Bone Joint J* 2015; 97-B:510–15.

The Achilles tendon is the thickest and strongest tendon in the body, but ruptures are common. The management of this injury remains controversial. Historically, it has been reported that conservatively managed ruptures will result in fewer complications; but the risk of re-rupture is reported to be higher at 13% compared with 5% after a surgically managed rupture.¹ The complications of surgery include infection and sural nerve damage.^{1,2} Recently, there have been reports of a lower re-rupture rate with conservative management involving functional orthoses.^{3,4} Wallace et al³ reported a rate of re-rupture of 2.9% in 945 patients, who were managed in this way.

Several factors probably influence the outcome. These include consideration of the inter-relationship between the characteristics of the pathology, the physiology of healing/tendon mechanics and the demands of the patient.

The crucial decisions include whether to treat surgically or not, how to immobilise the ankle, and what is the optimal rehabilitation, in particular when to re-introduce tendon loading. Many different protocols have been proposed for the use of orthoses,^{3,4} the duration of

immobilisation, and the degree of plantar flexion chosen. The two main specific complications of this injury are re-rupture and incorrect tendon length. Both are dependent on the location and completeness of the tear, and the proximity of the ends of the ruptured tendon.⁵ Ultrasound may be used to identify the location of the rupture, the amount of tissue torn and, importantly, the ability of the torn tendon tissue to oppose in varying positions of equinus.^{6,7} This is therefore an essential investigation. For patients who are treated conservatively, knowledge of the optimum position for immobilisation is obtained by using ultrasound to place the ankle in a position in which the ends of the tendon ends oppose, rather than overlap or fail to approximate.

Re-rupture occurs as a result of compromised mechanical properties of the healed tendon. The tensile strength of the tendon, and its ability to resist load, is dependent on the orientation and number of collagen filaments. Although the healing profile is likely to be dependent on the type and position of immobilisation, for both conservative and surgically managed patients, the subsequent loading

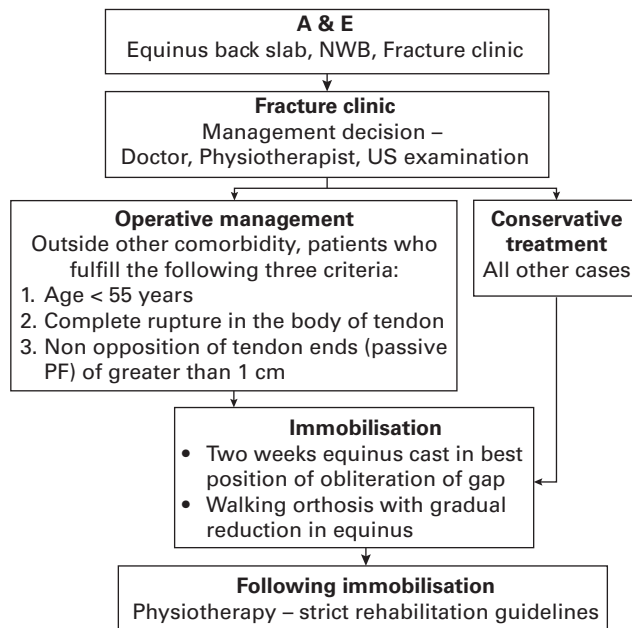


Fig. 1

Summary of the SMART protocol. (US, ultrasound, NWB, Non-Weight Bearing, PF, Plantar Flexion).

regime of the healed tendon will dictate the strength of the scar tissue and influence the likelihood of re-rupture.⁸⁻¹⁰ A structured, fully managed, staged rehabilitation protocol, both during and after immobilisation, is therefore essential.

The objective of the Swansea Morriston Achilles Rupture Treatment (SMART) protocol was to create rationalised decision-making for patients with a ruptured Achilles tendon and a rationalised and comprehensive rehabilitation regimen. We report the results of patients with a rupture of the Achilles tendon who were managed using this protocol.

Patients and Methods

Between January 2008 and January 2014 a total of 273 patients presented with an acute rupture of the Achilles tendon, all within two weeks of injury. Some patients who presented more than two weeks after injury were also treated using the protocol, but their results were not included in this study. There were 215 men and 58 women with a mean age of 46.5 years (20 to 86) (median 44, SD 14) six of whom were elite sports personnel. A total of 211 patients were treated conservatively and 62 underwent operative repair.

The protocol. The SMART protocol (Fig. 1) was established in 2008 with three main tenets of management: ultrasound examination; referral to a dedicated clinic with specialist physiotherapists rather than an orthopaedic surgeon and strict rehabilitation guidelines. Between 2008 and 2010, minor changes were made, such as updating the documentation forms and training other physiotherapists, but since then no further alterations have been made.

Ultrasounds scan assessment form for TA Ruptures

Side of injury: Left ☐ Right ☐

Time from injury: _____ days / weeks

Please tick if the tear is: Complete ☐ or Partial ☐

Rupture Site
Please mark on the diagram below the site of rupture.

Diagram showing Tendon, Calcaneus, and Rupture site.

Please shade the area of partial tear as: XXXX XXXX XXXX

Diagnostic confidence (please circle):

Poor	1	2	3	4	5	Excellent
------	---	---	---	---	---	-----------

Additional comment: _____

Gap size between tendons ends (mm) in:

Full Plantar Flexion	Full plantar flexion and 20° knee flexion	In 20-30° Plantar Flexion
_____ mm	_____ mm	_____ mm

Radiologist / Sonographer (print name): _____

Radiologist / Sonographer Signature: _____ Date: _____

Fig. 2

Ultrasound scan form completed by the Consultant Radiologist.

The protocol covers the period from presentation in the emergency department to discharge from care when the patient has returned to their required level of activity. The rupture was confirmed clinically at presentation using the Simmonds test,¹¹ a non-weight-bearing equinus back slab was applied, and a referral to the fracture clinic was arranged. A consultant musculoskeletal radiologist conducted an ultrasound examination of the Achilles tendon on a semi-urgent basis, preferably during the same or the next working day. The primary aim of this was to confirm the diagnosis. It also detailed the site and extent of the rupture and the smallest gap that could be achieved between the tendon ends in varying positions of equinus. The radiologist completed an injury-specific form (Fig. 2) to document this information.

Since 2011, the decision regarding conservative or surgical treatment has been more strongly influenced by the ultrasound findings. Operative management was advised for patients fulfilling all the following criteria: age < 55 years, rupture in the body of the tendon, and a gap of the tendon ends > 1 cm on passive plantar flexion. This rationale was based on the fact that function is likely to be impaired if the tendon heals with a gap of > 1 cm.¹² Use of ultrasound examination for all patients resulted in increased frequency of conservative management. Comorbidities

Table I. Management of patients during immobilisation period for operative and non-operative patients

Week	Conservative	Surgical
0 to 2	Equinus FWB cast with a wedge in the best position that opposes the tendon ends	Back slab NWB
2 to 5	Vacoped boot locked at 30 degrees FWB	Vacoped boot locked at 30° FWB
5 to 7	Vacoped boot 30° to 15° FWB Yellow theraband exercises for soleus and gastrocnemius	Vacoped boot 30° to 15° degrees Yellow theraband exercises for soleus and gastrocnemius
7 to 9	Vacoped boot 0-30 degrees with a flat wedge FWB	Vacoped boot 0-30 degrees with a flat wedge FWB
9 to 10	Vacoped boot fully unlocked FWB	Vacoped boot fully unlocked FWB
10 to 16	Removal of boot To wear only in vulnerable environments (6/52)	Removal of boot To wear only in vulnerable environments (6/52)

FWB, Full Weight Bearing, NWB, non weight bearing

Table II. Rehabilitation guidelines after immobilisation for operative and non operative patients)

Do	Do not
Weeks 10 to 12 post injury	
Issue patient with a heel raise for shoe	
Warn the patient that most re-ruptures occurs during this phase	
Advise the patient to avoid activities which involve extreme dorsi flexion of the ankle combined with active plantar flexion	
Advise the patient that they will not return to sports which involve running until they are 6 to 8 months post injury	
Advise the patient on a PWB gait pattern; particularly re-educating the toe off phase of gait	Do NOT attempt running, jumping or hopping
Work on ROM of the ankle and foot. Particularly length of soleus and gastrocnemius	
Lower limb muscle strength work. Particularly of the plantar flexors	Do NOT attempt eccentric lowering exercise off a step used for tendonopathies. Do not attempt resistance plantar flexion exercises which requires more than half the patients body weight
Proprioception exercises	
Gentle plyometric exercises	
Hydrotherapy – particularly good during this phase	
For surgical patients take care of the scar. Any sign of break down refer patient back to clinic as soon as possible	
3 to 5 months post injury	
Dispense of heel raise	
Continue to avoid activities of extreme dorsi flexion combined with active plantar flexion	
Aim to single leg heel raise	
Plyometric – progress for example start with 2 feet jumps (bunny hops), jogging on trampet, PWB jogging, i.e., leaning on table	
5 to 6 months post injury	
Gait – Start jogging on the flat	
Strength – start eccentric exercises off step	
Progress proprioceptive exercises as appropriate	
Sports specific rehab exercises	
6 to 8 months post injury	
Gait – introduce hill running	Return the patient to competitive sports until they can: single leg heel raise; sprint with the toe off phase of gait; until horizontal single leg hop x 3 is at least 75% of good leg and vertical hop is at least 75% of good leg
Introduce hopping and progress to long horizontal and vertical hops	
Return to sport as able	
ROM, range of movement	

were also considered. All patients with comorbidities considered as contra-indications to surgery were treated conservatively. Open injuries were always treated surgically. Non-operative management was selected for all other cases, including elite athletes (national representation, semi-professional and professional sports personnel).

The position of immobilisation was determined from the ultrasound scan. Patients in whom the gap was obliterated in full plantar flexion were placed in a below-knee weight-bearing cast in maximum equinus. This cast was retained for two weeks, after which a walking orthosis that enabled a gradual reduction in equinus was used.

Table III. Modification of final question on achilles tendon repair score

Score	
Excellent (15 points)	Single leg heel raise to same height as other leg, no hand support required
Good (10 points)	Single leg heel raise not to the same height as other leg, min hand support required
Fair (5 points)	Just about Single leg heel raise, maximum hand support required
Poor (0 points)	Unable to single leg heel raise

Table IV. Outcome scores at four, six and nine months post rupture

Mean score at:	Achilles tendon rupture score	Mean achilles repair score
4 months (n = 135)	53.0 (SD14)	64.9 (SD 15)
6 months (n = 103)	67.8 (SD 16)	73.8 (SD 15)
9 months (n = 43)	72.4 (SD 14)	72.3 (SD 13)

Table V. Annual cost implications of The Swansea Morriston Achilles Rupture Treatment protocol comparing 2008 and 2013

Increase costs
20 extra ultrasound scans per year at £60 per scan = £1200
Boots compared with cast × 3 £6867 (inclusive VAT)
Total = £8067
Decreased costs or savings
37 fewer operations at £2300 per operation + £400 a night hospital stay
Total = £99 900
Total saving = £ 91 813 per annum

If the tendon ends overlapped in full plantar flexion the ankle was dorsi-flexed to a position where the tendon ends opposed. It was important to flex and extend the knee during the ultrasound examination and to assess the amount of opposition of the tendon ends in varying positions of equinus, including 20° to 30° plantar flexion. This latter position could be provided by functional orthoses (Vacoped, Oped UK Ltd, Devizes, United Kingdom).

All patients were referred to an Achilles tendon clinic during the period of immobilisation, and their overall management was conducted by a specialist physiotherapist (Table I). Following removal of the orthosis, all patients were referred for physiotherapy at their local hospital with strict guidelines for rehabilitation (Table II) and were reviewed in the Achilles clinic until they had returned to their required activity demands. This varied between four and nine months after injury. The Achilles Tendon Rupture Score (ATRS), a valid and reliable outcome measure for Achilles tendon ruptures,¹³ and the Achilles Repair Score (AS)¹⁴ were completed. Both these scores are out of 100, with 100 being regarded as a perfect outcome. In the absence of an isokinetic machine, the final question of the AS was modified as described in Table III to include a single-leg heel-raise test to assess muscle strength.

If the physiotherapist at the achilles tendon clinic identified any problems, the patient was referred to a consultant

foot and ankle surgeon in conjunction with the specialist therapist.

Venous thromboprophylaxis was undertaken selectively. Any patient with a history or a family history of a deep vein thrombosis (DVT) or pulmonary embolism (PE) received low molecular weight heparin subcutaneously, once daily for the immobilisation period. All other patients were counselled about the risk of DVT and PE and anticoagulated if they agreed.

Statistical analysis. A descriptive data analysis was performed of the demographic details, the rate of re-rupture, outcome (ATRS and AS) and complications. The rate of re-rupture is presented as frequency data, the outcome scores as means and standard deviations (SD). The financial impact of the pathway was also analysed using an elementary health economics evaluation.

Results

The rate of re-rupture was 1.1% (3/273). Two patients with a re-rupture had been managed conservatively (2/211) and the other surgically (1/62). Two patients were non-compliant. One, who was managed surgically, was on steroid medication and the other, who was managed conservatively, was injured in a fight. The third patient, who was compliant, fell downstairs two weeks after removal of the orthosis. The ATRS and AS scores at four, six and nine months are shown in Table IV. The mean ATRS and AS at four months was 53.0 (SD 14), 64.9 (SD 15) (n = 135), six months 67.8 (SD 16), 73.8 (SD 15) (n = 103) and nine months 72.4 (SD 14) 72.3 (SD 13) (n = 43). Once patients had reached their required level of activity they were discharged from the clinic. Therefore, identical follow-up data was not available for all patients.

Operating selectively led to an estimated overall cost saving to the department of £91 813 per annum (Table V). This was in comparison with operative figures for patients with a rupture of the Achilles tendon prior to the instigation of the protocol. The major cost saving, associated with the introduction of the protocol was the shift from operative to non-operative treatment. In 2008/2009 just under half of patients with a rupture of the Achilles tendon were managed surgically. Between 2011 and 2013, only 6% of patients were treated operatively (Fig. 3). The change in the choice of treatment with the passage of time was not associated with any obvious changes in self-reported outcome (Fig. 3).

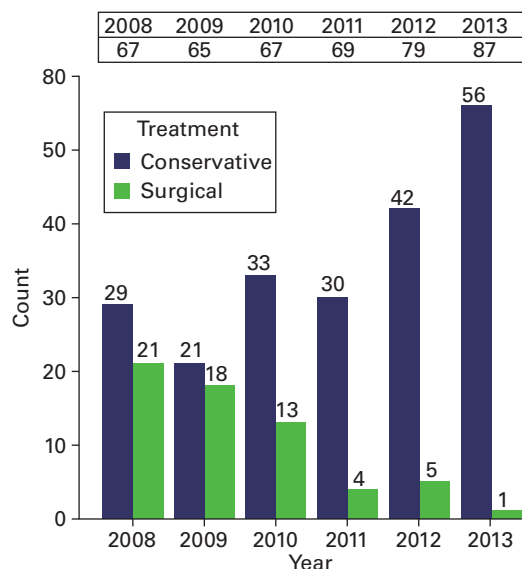


Fig. 3

Histogram demonstrating the change in management of operative to non-operative management with evolution of the SMART protocol. The change over time of the mean Achilles Tendon Rupture Score (ATRS) score nine months post-immobilisation is shown at the top to demonstrate consistency in outcome scores regardless of the change in management.

There were 23 major complications in addition to the three re-ruptures; 15 patients had a DVT (diagnosed on Doppler ultrasound scanner) and five had a PE (diagnosed on CT pulmonary angiography). In the 211 conservatively managed patients, 11 had a DVT and four a PE. In the 62 surgically managed patients four had a DVT and one had a PE. The overall rate of venous thrombo-embolism (VTE) was 7.3%. Three patients had a superficial wound infection. There were 11 minor complications, including soreness from the boot.

During the immobilisation period (either following surgery or during conservative management) most patients (264/273, 97%) were managed without further involvement of an orthopaedic surgeon; nine required review by an orthopaedic surgeon. The reasons for this were re-rupture ($n = 3$), suspected DVT ($n = 2$), wound infection ($n = 3$) and excessive pain ($n = 1$).

Discussion

These results demonstrate that the SMART protocol results in a low rate of re-rupture (three patients, 1.1%), a satisfactory outcome with a mean ATRS = 72.4 and mean AS = 72.3 at nine months and significant cost savings. These nine month scores are limited in terms of follow-up data available but a similar pattern is seen for both the four and six month follow-up data.

Although this study was not designed to show that any improvements in the rate of re-rupture resulted directly from the introduction of the new protocol, the findings are

persuasive. There are a number of possible reasons why the protocol could have resulted in this exceptionally low rate of re-rupture. First, decision-making for management is based on ultrasound, with the choice of operative management and/or the position of immobilisation being influenced by the findings. To our knowledge this is the first protocol to include a detailed ultrasound examination for this purpose. Other protocols describe positions for immobilisation irrespective of the amount of opposition of the ends of the tendon as seen on ultrasound in the plantar-flexed position.³ The results only relate to patients who have been assessed and begin treatment within two weeks of injury. Although data exist for those with delayed presentation, the analysis remains incomplete. Issues such as partial or non-closure of the gap resulting from organisation of a haematoma may confound the results for those patients with delayed presentation.

Secondly, all our patients were followed up during the immobilisation period in a specialised dedicated clinic. This standardised approach may maximise patient compliance and understanding of the injury. The role of the specialist physiotherapist is considered a key component, providing a dedicated service that allows the patient to develop an understanding of the management and treatment. Continuity of care is also important, and the provision of this by the specialist physiotherapist addresses the potential problem created by rotation of junior doctors and changes in working practice. Furthermore, the specialist physiotherapists had access to immediate support from orthopaedic consultants when required. The protocol requires a level of commitment, manpower and dedication that would be difficult to provide in a large standard fracture clinic.

Thirdly, following the period of immobilisation all patients followed a strict physiotherapy protocol. The progression of rehabilitation needs to be balanced against the risks of re-rupture and lengthening of the tendon. Strict guidelines throughout all parts of the rehabilitation process are therefore essential.

We report a rates of VTE of 7.5% (20/273); the incidence of symptomatic DVTs being 5.5% (15/273) and that of symptomatic PE 2% (5/273). This incidence of VTE is similar to that reported by Healy et al, 2010 who reported an incidence of 10 DVT and 3 PE from 208 patients that had ruptured their Achilles tendon.¹⁵ The thromboprophylactic management of patients with Achilles rupture is controversial. Our patients were treated selectively. Interestingly, both of the patients with a previous history of DVT sustained another DVT despite prophylaxis. Mechanical methods (i. e. graded compression stockings or intermittent pneumatic leg compression devices) in conjunction with the cast/orthosis, have proven ineffective.¹⁶

There are a number of limitations to this study. First, it was a descriptive case series aimed at monitoring our current practice, which has evolved over a period of five years, rather than an experimental study testing the efficacy of a treatment. Although it clearly shows potential benefit for

these patients, it is not a substitute for the proof afforded by a randomised controlled trial. Previous attempts to conduct a randomised study in our department failed because of a high level of patient preference for either non-surgical or surgical treatment. Secondly, the secondary outcome measures, the ATRS and AS scores, were not collected from all the patients (four months, $n = 135$; six months, $n = 103$; and nine months, $n = 43$), as patients were discharged from the clinic once they had returned to their required level of activity. In addition, we did not have access to isokinetic strength testing and included a single-leg heel-raise test to give an indication of muscle strength.

Although it was not our intention to conduct a study testing the efficacy of treatment, there was a need to review this newly adopted protocol for patient safety on an annual basis. We felt that it was important to share our case series report, albeit with the above limitations, as the rate of re-rupture appears to be the lowest reported to date.

This work has produced local and regional changes in how patients with a rupture of the Achilles tendon are managed. There has been a move away from an equal ratio of conservative to surgical management to one favouring conservative treatment. In addition, as the protocol was used for elite sports personnel, it suggests that the regime is safe and appropriate for the high-performance athlete. In order to achieve these goals, the SMART protocol requires a committed team approach and a good relationship between the orthopaedic surgeons, radiologists, physiotherapists and nurses.

This protocol is a pragmatic approach to the management of patients with a rupture of the Achilles tendon that can easily be followed by most healthcare providers. Most importantly, this change has resulted in improved outcomes, a reduced rate of re-rupture, a reduction in surgical intervention and cost savings.

Author contributions

A. M. Hutchison: Protocol development, review and amendment, data collection and analysis, writing of manuscript, performed clinic reviews and rehabilitation.

C. Topliss: Part of team setting up protocol with regular review and amendment. Review of paper. Review of problem patients and support of clinic when required

D. Beard: Project design and guidance, some analysis, writing and editing of manuscript.

R. M. Evans: Writing paper, performing ultrasound scans.

P. Williams Supervising Clinical Consultant, algorithm development, decision making & management, surgery, data analysis, writing manuscript.

We thank the consultant orthopaedic surgeons, consultant musculoskeletal radiologists, musculoskeletal physiotherapists and fracture clinic nursing staff

at Morriston Hospital, Swansea, for their support in the development of the SMART protocol.

A. M. Hutchison received modest educational support from OPED UK Ltd (Medical Devices) to attend a conference

The author or one or more of the authors have received or will receive benefits for personal or professional use from a commercial party related directly or indirectly to the subject of this article.

This article was primary edited by G. Scott and first proof edited by J. Scott.

References

1. Khan RJ, Fick D, Keogh A, et al. Treatment of acute achilles tendon ruptures. A meta-analysis of randomized, controlled trials. *J Bone Joint Surg [Am]* 2005;87-A:2202–2210.
2. Amendola A. Outcomes of open surgery versus nonoperative management of acute achilles tendon rupture. *Clin J Sport Med* 2014;24:90–91.
3. Wallace RG, Heyes GJ, Michael AL. The non-operative functional management of patients with a rupture of the tendo Achillis leads to low rates of re-rupture. *J Bone Joint Surg [Br]* 2011;93-B:1362–1366.
4. Wallace RG, Traynor IE, Kernohan WG, Eames MH. Combined conservative and orthotic management of acute ruptures of the Achilles tendon. *J Bone Joint Surg [Am]* 2004;86-A:1198–1202.
5. Silbernagel KG, Steele R, Manal K. Deficits in heel-rise height and achilles tendon elongation occur in patients recovering from an Achilles tendon rupture. *Am J Sports Med* 2012;40:1564–1571.
6. Qureshi AA, Ibrahim T, Rennie WJ, Furlong A. Dynamic ultrasound assessment of the effects of knee and ankle position on Achilles tendon apposition following acute rupture. *J Bone Joint Surg [Am]* 2011;93-A:2265–2270.
7. Trickett RW, Hodgson P, Lyons K, Thomas R. Effect of knee position on gap size following acute Achilles rupture. *Foot Ankle Int* 2011;32:1–4.
8. Von Forell GA, Hyung PS, Bowden AE. Failure modes and fracture toughness in partially torn ligaments and tendons. *J Mech Behav Biomed Mater* 2014;35:77–84.
9. Schepull T, Aspenberg P. Early controlled tension improves the material properties of healing human achilles tendons after ruptures: a randomized trial. *Am J Sports Med* 2013;41:2550–2557.
10. Krapf D, Kaipel M, Majewski M. Structural and biomechanical characteristics after early mobilization in an Achilles tendon rupture model: operative versus nonoperative treatment. *Orthopedics* 2012;35:1383–1388.
11. Simmonds FA. The diagnosis of the ruptured Achilles tendon. *Practitioner* 1957;179:56–58.
12. Costa ML, Logan K, Heylings D, Donell ST, Tucker K. The effect of achilles tendon lengthening on ankle dorsiflexion: a cadaver study. *Foot Ankle Int* 2006;27:414–417.
13. Ganestam A, Barfod K, Klit J, Troelsen A. Validity and reliability of the Achilles tendon total rupture score. *J Foot Ankle Surg* 2013;52:736–739.
14. Leppilahti J, Forsman K, Puranen J, Orava S. Outcome and prognostic factors of achilles rupture repair using a new scoring method. *Clin Orthop Relat Res* 1998;346:152–161.
15. Healy B, Beasley R, Weatherall M. Venous thromboembolism following prolonged cast immobilisation for injury to the tendo Achillis. *J Bone Joint Surg [Br]* 2010;92-B:646–650.
16. Domeij-Arverud E, Latifi A, Labruto F, Nilsson G, Ackermann PW. Can foot compression under a plaster cast prevent deep-vein thrombosis during lower limb immobilisation? *Bone Joint J* 97-B1227–1231.